

## Evaluation of wound healing activities of *Vitex doniana* (Black Plum) ethanol fruit extract

Victoria Nonyelum Olli <sup>1</sup>, Ernest Chima Orji <sup>2</sup> and Jude Nnaemeka Okoyeh <sup>3,\*</sup>

<sup>1</sup> Department of Pharmacology and Toxicology, Chukwuemeka Odumegwu Ojukwu University Igbariam campus Nigeria,

<sup>2</sup> Department of Pharmacology and Toxicology, Faculty of Pharmaceutical Sciences, Nnamdi Azikiwe University, P.M.B 5025 Awka, 420110 Anambra state, Nigeria.

<sup>3</sup> Department of Medical Laboratory Science and Biology, School of Nursing and Health Sciences, Neumann University, One Neumann Drive, Aston, PA, 19014. USA

World Journal of Advanced Research and Reviews, 2024, 24(01), 415–423

Publication history: Received on 20 August 2024; revised on 28 September 2024; accepted on 30 September 2024

Article DOI: <https://doi.org/10.30574/wjarr.2024.24.1.3004>

### Abstract

In this study, the folkloric use of *Vitex doniana* fruit extract for the treatment of wounds was evaluated. The mesocarps of the fresh fruits were removed, oven-dried at 40°C and pulverized. The powdered material (800 g), was exhaustively macerated in 80 % ethanol, filtered and dried in a water bath at 40°C. Phytochemical screening and acute dermal toxicity of the extract were investigated. Herbal ointments (10 and 50 %w/w) were formulated using soft paraffin base. The wound-healing effect of the extract was carried out using twenty albino rats divided into four groups (n=5). Groups I (soft paraffin) and II (10 %w/w Povidone-iodine) served as negative and positive controls, respectively. Groups III and IV were topically treated with 10 %w/w and 50 %w/w of the herbal ointment respectively. Treatments and wound grading were assessed once daily and every 4 days, respectively, as well as the timeframe for percentage wound contraction and epithelialization. Both the 10 %w/w and 50 %w/w herbal ointments exhibited a concentration-related significant (P<0.05) wound contraction when compared to the control. Epithelialization period of 50 %w/w extract was less than that of the standard drug. The wound closure area of 50 %w/w extract was >positive control >10 %w/w extract > negative control. Histological study of the wounds on the 16th day indicated no sign of dermal toxicity. Some secondary metabolites such as alkaloids and tannins were present. In conclusion, the folkloric use of the fruit extract of *V. doniana* for the treatment of wounds may therefore be justified

**Keywords:** *Vitex doniana*; Wound-contraction; Epithelialization Wound-closure; Herb

### 1. Introduction

Medicinal plants remain the foremost therapeutic alternative for majority of people in developing world [1]. These plants have the advantage of being easily available, cheap, less toxic and well tolerated by humans since majority of them are already sources of food to local users. As health care costs continue to escalate, the attraction for low-cost medicinal remedies has stimulated the interest of consumers to re-evaluate the potential of alternatives [2]. According to Gbile and Adesina [3], the rich Nigerian flora has made and would continue to make great contributions to health care of Nigerians.

\* Corresponding author: Jude Nnaemeka Okoyeh



**Figure 1** The tree and fruits of *Vitex doniana* (Black Plum)

*Vitex doniana* tree (*Verbenaceae*) is a medium-sized deciduous tree, 8-18m high, with a heavy rounded crown and a clear bole up to 5m. It can be found throughout tropical Africa [4]. The fruit is commonly known as Black Plum (English), Dinya in (Hausa), Mbembe (Igbo), Oriri (Yoruba) by some ethnic groups in Nigeria. It is a well-known plant widely distributed in South East Nigeria [5] with multiple uses such as food (both leaves and fruits) and medicines. It is commonly used in traditional settings for the management of a number of diseases, a decoction of the woody parts of the plant is used for the treatment of inflammatory disorders, stomach pains, diarrhea, rheumatic pains and dysentery [6]. The plant is known for its fruit which serves as a delicacy for majority of people, especially in the Eastern part of Nigeria. The use of the fruit is widespread; however, some of its folkloric uses have not been scientifically investigated

A wound can be defined as a damage to the normal anatomy and function of the skin [7]. This may vary from a minor injury of epithelial tissues of the skin to a deeper damage to the subcutaneous tissue, blood vessels, muscles, tendons, bones, parenchymal organs, and nerves [7]. They may have an intentional or accidental aetiology or could be as a result of a disease state [8]. Current methods of wound management include the use of antibiotics, proteolytic enzymes and tissue grafts which can be associated with major drawbacks such as invasiveness and higher cost [9]. Emergence of multi-drug resistant strains of bacteria, poverty, high cost of treatment has led to increase in wound-related mortality and morbidity [10]. Multi-drug resistant strains are most of the common influencing factor of non-healing wounds and remains a significant burden for patients and caregivers [10]. Different studies are being carried out across the world to uncover agents that can facilitate wound healing in order to minimize hospitalization costs and save the patient from amputation and other serious complications. Phytomedicines for wound healing can reduce costs, adverse effects, and antibiotic resistance [8]. However, there is need for scientific confirmation, standardization, and safety assessment of plant extracts, like *Vitex doniana* fruit extract.

## 2. Material and methods

### 2.1. Plant materials

The fresh fruits of *Vitex doniana* were purchased from Ekwulobia town in Anambra State, Nigeria, and were authenticated by a Taxonomist at the Department of Botany, Nnamdi Azikiwe University, Awka, Nigeria. It was assigned herbarium specimen, (NAUBT 3218) and kept in the Herbarium.

### 2.2. Animals

A total of twenty-three albino rats of both sexes (120-150 g) were obtained from the Animal House of the Department of Pharmacology and Toxicology, Chukwuemeka Odumegwu Ojukwu University (COOU), Anambra State, Nigeria. The rats were housed in clean well-ventilated plastic cages, supplied with clean drinking water and fed with commercially available pelletes (Guinea Feed®, Nigeria). Ethical approval number (PHACOOU/AREC/2023/036) was assigned to attest that the animals were cared for according to the Faculty of Pharmacy (COOU) Animal Research Ethics Committee guidelines (PHACOOUAREC), which were in line with the National Institute of Health (NIH), USA, guidelines for the care and use of laboratory animals.

### 2.3. Extraction of plant materials

After washing the fresh fruits under running water, the exocarps of the fruits were peeled off and discarded. Then the fleshy mesocarp was removed and oven-dried at 40°C for 48 h. After drying, it was pulverized into fine powder using an electrical grinding machine. About 800 g of the powdered material was macerated in 80 % ethanol. The mixture was agitated continually for three days (72 hours). Thereafter, the macerated product was first filtered through a cotton plug and further filtered with filter paper (Whatman filter paper, No 1). The filtrate was concentrated to dryness using a water bath at 40°C and the percentage yield of the extract was determined. The dried extract was stored in a refrigerator until used

### 2.4. Phytochemical analysis

Phytochemical screenings of the extract for the presence of secondary metabolites such as terpenoids, saponins, alkaloids, flavonoids, tannins, and cardiac glycosides were carried out using standard qualitative methods as described by Trease and Evans [11].

#### 2.4.1. Formulation of the herbal ointment

White soft paraffin was used as the base. The base (25 g) was melted in a water bath at 40°C. Into this melted white soft paraffin in a mortar, different concentrations of the fruit extract were incorporated and stirred gently and continuously until a homogenous dispersion was observed in order to get 10 and 50 %w/w herbal ointments, and the herbal ointments were allowed to solidify before use [13].

#### 2.4.2. Acute dermal toxicity study

The acute dermal toxicity test of the fruit extract was assessed as per OECD (organization for economic co-operation and development) draft guideline number OECD 404[12] (2015). Three female albino rats, having normal skin surface were randomly selected, maintained in a cage individually and acclimatized to the laboratory environment for a week prior to the commencement of the test. About 10 % of the body surface area fur of the rat was shaved from the dorsal area of the trunk 24 hours prior to study. The extract formulation 10 %w/w, was uniformly applied over the shaved area and allowed to remain there for 24 hours. The residual test substance was removed at the end of the exposure period of 24 hours and the rats observed daily for 14 days for any adverse skin reactions [7].

### 2.5. Wound healing evaluation of the extract

#### 2.5.1. Grouping and dosing

Twenty albino rats of both sexes were randomly assigned into four groups (n=5) and treated as follows:

- Group I: Soft paraffin (Negative control)
- Group II: Povidone-iodine treated 10 %w/w (Positive control)
- Group III: Fruit extract (10 %w/w)
- Group IV: Fruit extract (50 % w/w)

### 2.6. Creation of excisional wounds

The excisional wounds were created after shaving the left dorsal thoracic region 1cm away from the vertical column and 5 cm away from the ear. The animals were anesthetized during the creation of wounds with chloroform using open mask method. Excision wound of about 3 cm in diameter were created. All wounds were of full thickness, extending down to adipose tissue [14]. The wound area was measured immediately by placing a transparent tracing paper over the wound and traced. The tracing paper was subsequently placed on 1 mm<sup>2</sup> graph sheet, and traced out too. The squares on the graph sheet were counted and the area was recorded [15].

### 2.7. Wound treatment and grading

The wound areas were measured every 4 days by retracing the wounds on a millimeter scale graph paper [16]. The wounds were cleaned daily with methylated spirit and the appropriate ointment and standard drug applied once a day until complete healing was observed. Epithelialization time was noted as the number of days required for the scab to fall off after the wound infliction leaving no raw wound behind [17]. Wound contraction was calculated as percentage reduction in wound area with respect to the initial wound area [18].

$$\% \text{ Wound contraction} = \frac{\text{Area of wound on day 0 (w0)} - \text{Area of wound on indicated day (w1)} \times 100}{\text{Area of wound on day 0 (w0)}}$$

## 2.8. Histopathological analysis

On 16<sup>th</sup> day, part of the excision skin tissues from all the groups were processed for the histopathological examination. The samples were fixed in 10 % buffered formalin, blocked with paraffin and then sectioned into 5 mm thickness. They were processed and stained with haematoxylin and eosin (H-E) dye [19] and photographed using Nikon digital microscope (Eclipse 200, Nikon instruments Inc., Melville, NY).

## 2.9. Statistical analysis

Data obtained from the study were analyzed using Statistical Package for Social Sciences (SPSS-25). Results were presented as Mean  $\pm$  Standard Error of the Mean (SEM) of sample replicates. Raw data were subjected to one-way analysis of variance (ANOVA) followed by post hoc Tukey's test, and  $P < 0.05$  was considered to be statistically significant.

## 3. Results

### 3.1. Yield of extract

The weight of the pulverized *V. doniana* fruit was 800g and the crude extract obtained from it was 257g. The percentage yield was 32 %w/w.

### 3.2. Phytochemical screening of the fruit extract

The qualitative phytochemical screening of the fruit extract revealed the abundance of alkaloids, tannins, flavonoids, glycosides, saponins, moderate presence of fats and oil, acidic compounds with traces of reducing sugar (Table 1).

**Table 1** Qualitative phytochemical screening of the fruit extract

Tannin	Flavonoid	Steroid	Saponin	Fats & Oil	Acidic Compds	Gly	Proteins	Alk	Reducing sugar
+++	+++	+++	+++	++	++	+++	++	+++	+

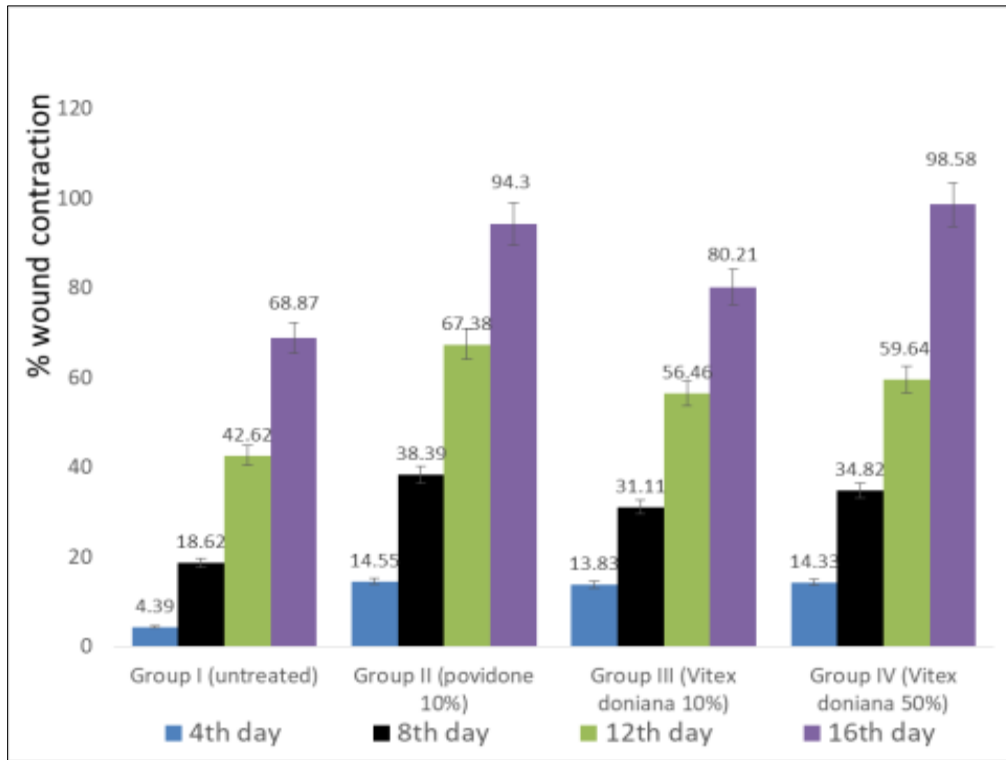
Key: (+) = faintly present, (++) = moderately present, (+++) = abundance Gly=glycoside, Alk=alkaloids, Compds=compounds

### 3.3. Acute dermal toxicity study of the fruit extract

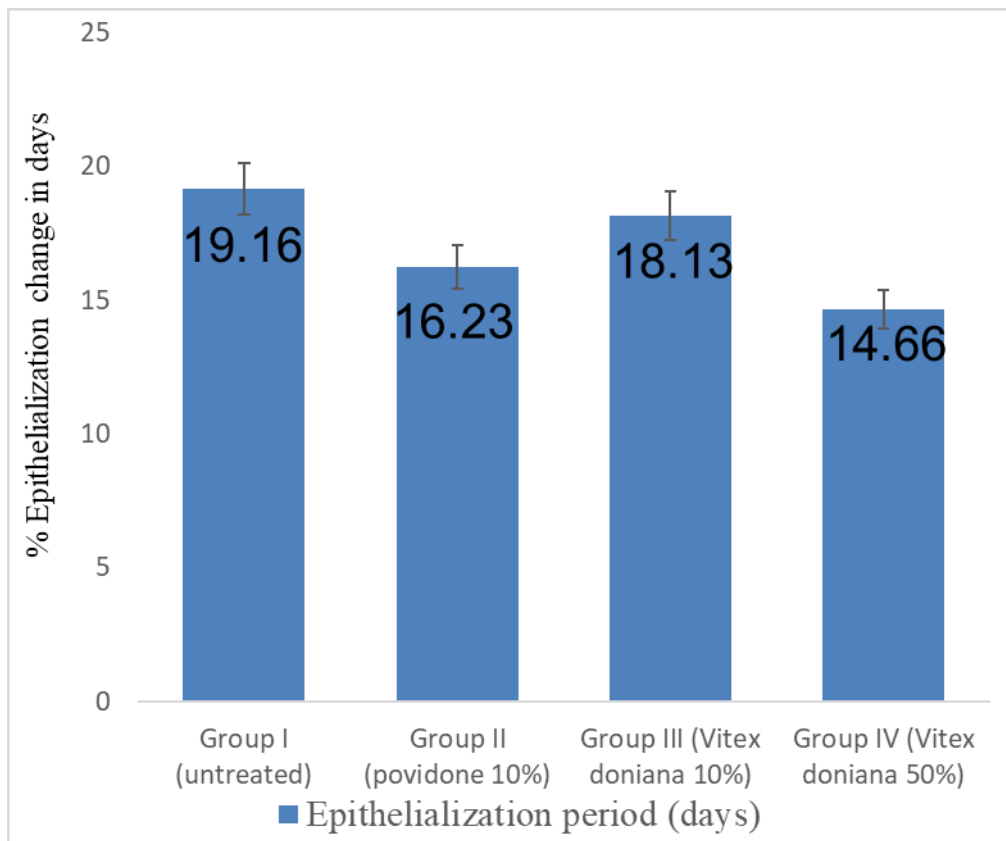
After 24 hours of application of 10 %w/w formulation of the extract, no dermal toxicity (inflammation, irritation, or redness) was observed. There was also no mortality after 48 hours and for 14 consecutive days of observation.

### 3.4. Effect of the extract on wound contraction and epithelialization period.

The two concentrations of the extract (10 and 50 %w/w) exhibited a concentration-related significant ( $P < 0.05$ ) wound contraction from day four of treatment when compared to the control (Figure 2). However, the wounds treated with the 50 %w/w extract healed faster than those of the standard drug as could be observed in their respective epithelialization periods (14.66 days) and (16.23 days) respectively (Figure 3).



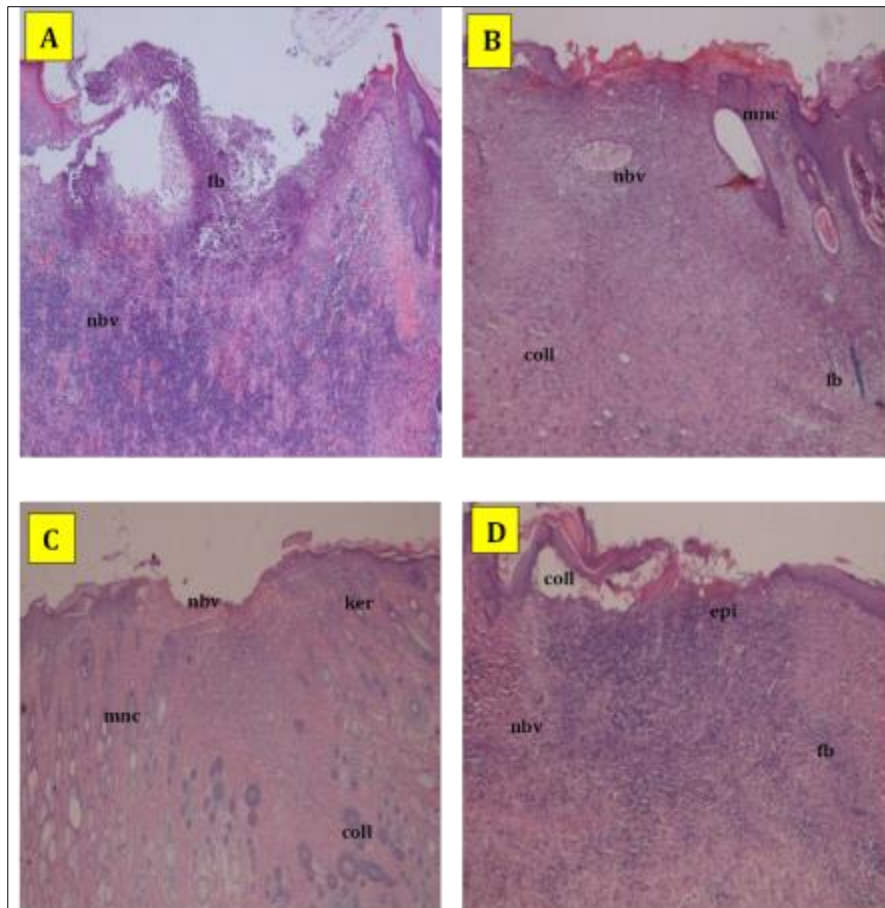
**Figure 2** Effect of the extract on wound contraction



**Figure 3** Effect of the extract on epithelialization period (Days)

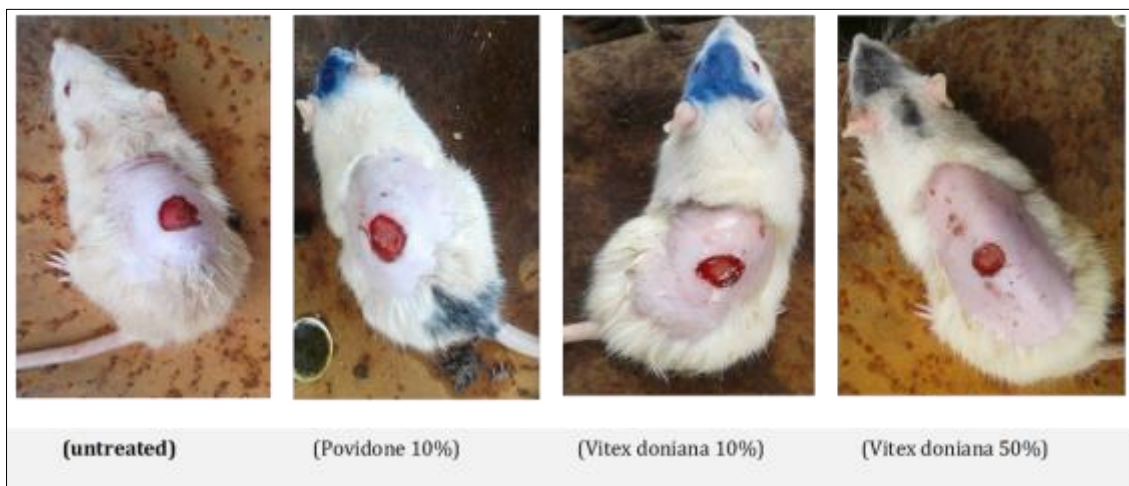### 3.5. Effect of the extract on wound enclosure

Histological result revealed that the 10 %w/w extract treated group (Figure 4C, Figure 5B) had an appreciable wound closure area on day 16, while that for 50 %w/w extract was 100 % (Figure 4D and Figure 5B). In comparison, the wound closure areas for 50 %w/w extract was >positive control >10 %w/w extract > negative control (Figure 5B).



**Key:** fb: Fibroblast cell; mnc: Mononucleated cell; epi: Epithelization; ker: Keratinization; nbv: New blood vessel; coll: Collagen

**Figure 4** Histological section of wound enclosure area



**Figure 5A** Day 1



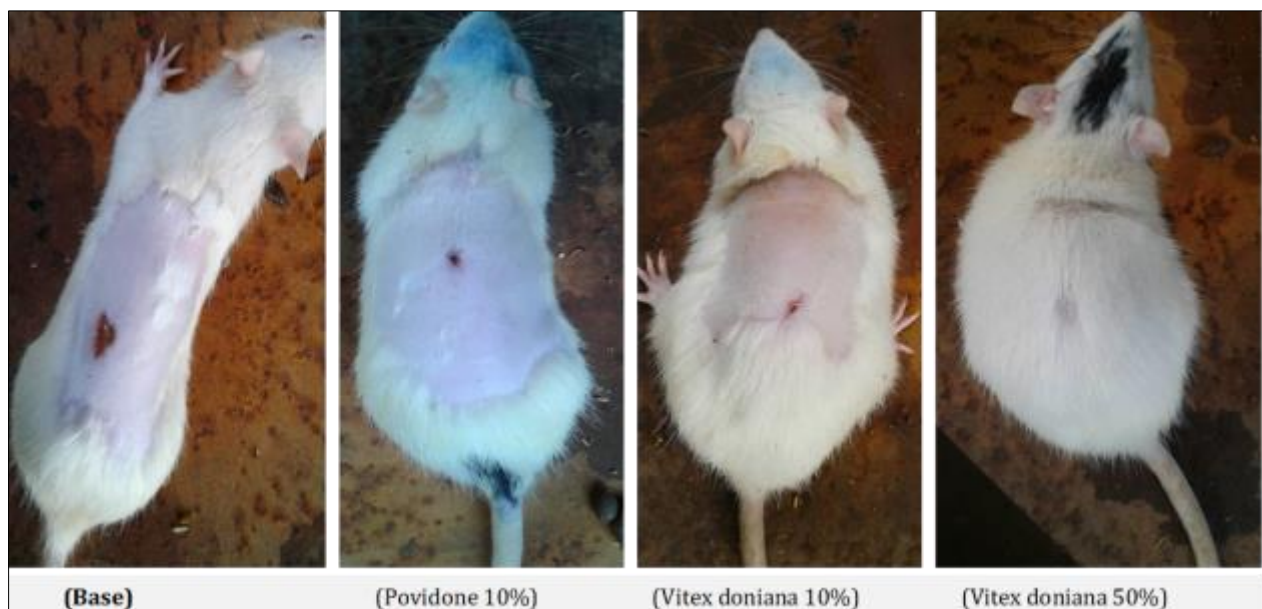


Figure 5B Day 16

#### 4. Discussion

Medicinal plant extract promotes wound healing with less pain, less discomfort, and less scar on the patient [20]. After 14 days of dermal application of the extract (10 %w/w), there was neither dermal toxicity nor death, therefore the fruit extract of *Vitex doniana* is relatively safe. The phytochemical screening of the fruit extract revealed abundance of alkaloids, tannins, flavonoids, glycosides and saponins with traces of reducing sugar. The wound healing potentials of some of these phytoconstituents have been reported in other studies [21].

From day four of treatment, the extract exhibited a concentration related significant ( $P < 0.05$ ) wound contraction when compared to the control. Wound contraction is known to contribute to wound closure [22], and wound contraction plays a crucial role as it decreases the dimension of the wound and hence shortens the healing time. Moreover, contraction reduces the extracellular matrix needed to repair the defect and helps re-epithelization by reducing the distance travelled by migrating keratinocytes [23]. On the other hand, epithelization period is time period it takes epithelial reorganization to take place. The 50 %w/w herbal ointment had lesser epithelization period (14.66 days) than the standard treatment (16.23 days). The observed wound contraction and decrease in epithelization period exhibited by the extract could be attributed to the phytoconstituents present in the extract. Flavonoids reduce the formation of inflammatory metabolites by inhibiting both cyclooxygenase and lipoxygenase activities [24]. Flavonoids also prevent neutrophil degranulation, which is a direct way to diminish the release of arachidonic acid by neutrophils and other immune cells [25]. The astringent and antimicrobial properties of phytochemicals may be responsible for wound contraction and increased epithelization rates [26]. Tannins are active detoxifiers and inhibit bacterial growth [27].

Conventional wound treatment requires, more or less, combined effects of antibiotics, anti-inflammatory agents, astringents, and antipyretics. *Vitex doniana* extract has been reported to possess anti-inflammatory and antioxidant [28], antimicrobial [29], and analgesic properties [30]. The observed increased wound enclosure area by the extract also confirms the wound healing effects of the fruit extract of *Vitex doniana*. The findings of this study collaborates the folkloric use of the fruit extract of *Vitex doniana* for the treatment of wounds.

#### 5. Conclusion

The findings of this study collectively showed that the fruit extract of *Vitex doniana* possessed significant wound healing activity; It therefore could be useful as an alternative herbal therapy for wounds. The way forward is performing quantitative phytochemical study to quantify the active components against wounds from this fruit extract.

---

## Compliance with ethical standards

### *Disclosure of conflict of interest*

The authors declare no conflict of interest.

### *Statement of ethical approval*

Ethical approval number (PHACOOU/AREC/2023/036) was assigned to attest that the animals were cared for according to the Faculty of Pharmacy (COOU) Animal Research Ethics Committee guidelines (PHACOOUAREC), which were in line with the National Institute of Health (NIH), USA, guidelines for the care and use of laboratory animals.

---

## References

- [1] dos Santos MM, Olaleye MT, Ineu RP, Boligon AA, Athayde ML, Barbosa NB, Rocha JBT. Antioxidant and antiulcer potential of aqueous leaf extract of *Kigelia africana* against ethanol-induced ulcer in rats. *Experimental and Clinical Sciences Journal*. 2014;13: 323-330
- [2] Gbile ZO, Adesina S K. Nigerian flora and its pharmaceutical potentials. *Journal of Ethnopharmacology*. 1986; 19: 1-6.
- [3] Bouldin, AS, Smith MC, Garner DD, Szeinbach SL, Frate DA, Croom M. *Pharmacy and herbal medicine in the US. Social Science and Medicine*. 1999; 49, 279–289
- [4] Hans-Jurgen VM. Trees and Shrubs of the Sahel. Their characteristics and uses. *Verlag Josef Magerat Scientific Book*.1990; 34
- [5] Agbafor KN, Nwachukwu N. Phytochemical Analysis and Antioxidant Property of Leaf Extracts of *Vitex doniana* and *Mucuna pruriens*. *Biochemistry Research International*, 2011; 459839: 1-4.
- [6] Ezekwesili CN., Ogbunugafor HA., Ezekwesili-Ofili JO. Anti-diabetic activity of aqueous extracts of *Vitex doniana* leaves and *Cinchona calisaya* bark in alloxan-induced diabetic rats. *International Journal of Tropical Diseases* 2012; 2(4):290–300
- [7] Son YJ, John WT, Zhou Y, Mao W, Yim EK, Yoo HS. Biomaterials and controlled release strategy for epithelial wound healing. *Biomaterial Science*. 2019;7(11):4444–4471.
- [8] Flangan M. The physiology of wound healing. *Journal of wound care*. 2000; 9:299–300. doi:10.12968/jowc.2000.9.6.25994
- [9] Muluye AB, Desta AG, Abate SK. Anti-malarial activity of the root extract of *Euphorbia abyssinica* (*Euphorbiaceae*) against Plasmodium berghei infection in mice. *Malaria Journal* 2019;261.
- [10] Atkin L. Understanding methods of wound debridement. *British Journal of Nursing*. 2014; 23(12): S10–S5. doi:10.12968/bjon.2014.23. sup12.S10
- [11] Trease GE, Evans WC, Bralliar TC. In *Pharmacognosy*, 11th edition. Macmillian Publishers: New York, NY, USA,1989; 3 110
- [12] OECD 404 Guidelines for the Testing of Chemicals. Acute dermal irritation/corrosion. *OECD Guidelines for Testing of Chemical Health Effects*. 2015; 1–8
- [13] Umeh VN, Ilodigwe EE, Ajaghaku DL, Erhirhie OE, Moke GE, Akah PA. Wound-healing Activity of the Aqueous Leaf Extract and Fractions of *Ficus exasperata* (*Moraceae*) and its Safety Evaluation on Albino Rats. *Journal of Traditional and Complementary Medicine* (2014); 4(4), 246-252; DOI: 10.4103/2225-4110.139105.
- [14] Morton JJ, Malone MH. Evaluation of vulnerary activity by an open wound procedure in rats. *Archives of Pharmacodynamics and Therapeutics* 1972; 196:117-26
- [15] Abdulla MA, Al-Bayaty FH, Younis LT, Abu Hassan MI. Antiulcer activity of *Centella asiatica* leaf extract against ethanol-induced gastric mucosal injury in rats. *Journal of Medicinal Plants Research*.2010; 4(13) , 1253-1259
- [16] Reddy JS, Rao PR, Reddy MS. Wound healing effects of *Haliotropium indicum*, *Plumbago zeylenicum* and *Acalypha indica* in rats. *Journal of Ethinopharmacology*. 2002; 79:249-51



- [17] Nayak BS, Pinto PLM. *Catharanthus roseus* flower extract has wound healing activity in Sprague Dawley rats. *BioMed Central Complement Alternative Medicine* 2006; 6(41), 1–6. <https://www.researchgate.net/publication/349607214>
- [18] Chah F, Dumas M, Chaudagne C, Meybeck, A. Influence of asiatic acid, madecassic acid, and asiaticoside on human collagen I synthesis. *Journal of medicinal plant research*.2006; 60(2), 133-135.
- [19] Murthy S, Gautam MK, Goel S, Purihit V, Sharma H, Goel RK. Evaluation of in vivo wound healing activity of *Bacopa monniera* on different wound model in rats. *BioMed Central Complement Alternative Medicine*. 2013; 2(1). <https://doi.org/2013.972028>
- [20] Fikru A, Makonnen E, Eguale T, Debella A, Mekonnen GA. Evaluation of in vivo wound healing activity of methanol extract of *Achyranthes aspera*. *Journal of Ethnopharmacology* 2012;143(2):469–474. doi: 10.1016/j.jep.2012.06.049
- [21] Mulisa E, Asres K, Engidawork E. Evaluation of wound healing and anti-inflammatory activity of the rhizomes of *Rumex abyssinicus* J. (*Polygonaceae*) in mice. *BioMed Central Complement Alternative Medicine*. 2015;15(1):341. doi:10.1186/s12906-015-0878-y
- [22] Collier M. Recognition and management of wound infections. *World Wide Wounds*. 2004; 7:8–14.
- [23] Mukherjee PK, Verpoorte R, Suresh B. Evaluation of in-vivo wound healing activity of *Hypericum patulum* (Family: *hypericaceae*) leaf extract on different wound model in rats. *Journal of Ethnopharmacology*. 2000;70(3):315–321. doi:10.1016/S0378-8741(99)00172-5
- [24] Robert JN, Els N, Danny EC, Petra GB, Klaske N, Paul L. Flavonoids: a review of probable mechanisms of action and potential applications. *American Journal of Clinical Nutrition*.2001; 74:418–425. doi:10.1093/ajcn/74.4.418
- [25] Akele B. In vivo anti-inflammatory and anti-nociceptive activities of arial part extracts of *Zehneria scabra*. *International journal of Pharmacy pharmaceutical research*. 2012; 2(4):479–484
- [26] Mekonnen NA, Atnafie AS, Atta WM. Evaluation of the anti-inflammatory activities of 70% ethanol leaves extract and solvent fractions of *Zehneria scabra* (Lf) Sond (*Cucurbitaceae*) in rodents. *Evidence Based Complementary Alternative Medicine* .2020; 2020:11.
- [27] Du Toit K, Drewes SE, Bodenstern J. The chemical structures, plant origins, ethnobotany and biological activities of homoisoflavanones. *Natural Product Research*. 2010;24(5):457–490. doi:10.1080/14786410903335174
- [28] Adjei S, Amponsah IK, Bekoe SO., Harley BK., Mensah KB., Mensah AY., Baah, MK Fosu-Mensah G. Fruits of *Vitex doniana* sweet: toxicity profile, anti-inflammatory and antioxidant activities, and quantification of one of its bioactive constituent oleanolic acid, 2021;7(9), 5-12. <https://doi.org/10.1016/j.heliyon.2021.e07910>
- [29] Khan AV, Ahmed, QU, Shukla I, Khan AA. Antibacterial activity of leaves extracts of *Trifolium alexandrinum* Linn. against pathogenic bacteria causing tropical diseases. *Asian Pacific Journal of Tropical Biomedicine*, (2012); 2(3), 189–194. [https://doi.org/10.1016/S22211691\(12\)60040-9](https://doi.org/10.1016/S22211691(12)60040-9)
- [30] Hussein R, El-Anssary A. Plants Secondary Metabolites: The Key Drivers of the Pharmacological Actions of Medicinal Plants. *IntechOpen*. (2019). <https://doi.org/10.5772/intechopen.76139>.