



(CASE REPORT)



Association of Gougerot-Sjögren syndrome and pulmonary adenocarcinoma: A case report

Loubna Ajdir *, Meriam El Mouden, Mohamed Ijim, Oussama Fikri and Lamyae Amro

Department of Pulmonology, Faculty of Medicine and Pharmacy, Caddy Ayad Universit, Errazi Hospital, Mohammed VI University Hospital, Marrakech, Morocco.

World Journal of Advanced Research and Reviews, 2024, 24(01), 1198–1203

Publication history: Received on 29 August 2024; revised on 06 October 2024; accepted on 09 October 2024

Article DOI: <https://doi.org/10.30574/wjarr.2024.24.1.3091>

Abstract

Interstitial lung disease represents the primary pulmonary involvement in Sjögren's syndrome. A number of patients with Sjögren's syndrome develop a progressive fibrosing form of interstitial lung disease, but there is no data on the prevalence of such presentations. The incidental association of malignant tumors has been described independent of any therapy.

We report a case of a patient with chronic interstitial lung disease at the fibrosis stage secondary to Sjögren's syndrome, in whom bronchoscopy incidentally revealed metastatic pulmonary adenocarcinoma.

Keywords: Diffuse interstitial lung disease; Fibrosis; Sjögren's syndrome; Pulmonary adenocarcinoma; Metastases

1. Introduction

Gougerot-Sjögren syndrome (GSS) is an autoimmune disease of the salivary and lacrimal exocrine glands, responsible for a clinical dry syndrome. While it may have been considered an organ-specific autoimmune disease, the presence of visceral involvement gives it a currently recognized systemic dimension. This lymphoexocrine syndrome is distinguished from other systemic diseases by its potential progression to genuine lymphoid proliferations, ranging from pseudolymphoma to confirmed lymphoma, creating a continuous lymphoproliferative spectrum [1-2]. The lung, like the hematopoietic organs and the central nervous system, is a primary target of this lymphoproliferative continuum, whose diagnosis is difficult in the absence of anatomopathological confirmation [3].

2. Case presentation

Mrs. A.F., a 72-year-old woman exposed to wood smoke and poultry and livestock droppings, has been chronically dyspneic at Sadoul stage II for 3 years. She consulted for a worsening of her dyspnea, which has progressed to Sadoul stage III, associated with a productive cough bringing up yellowish sputum sometimes streaked with blood, without chest pain. Additionally, the patient reports extra-thoracic signs such as xerophthalmia associated with xerostomia and inflammatory-like polyarthralgia. All of this is evolving in a context of apyrexia and general health decline. She had no history of cancer. The general examination found a conscious patient, hemodynamically and respiratorily stable, with a WHO performance status of 1. The pleuropulmonary examination revealed bilateral basal crackles and wheezes. The examination of the lymph node areas revealed a unilateral left cervical lymphadenopathy of 3 cm, hard in consistency, fixed, and painful on palpation, without inflammatory signs.

* Corresponding author: Loubna Ajdir

The angiotensin-converting enzyme level was normal, the search for Bk and the x-Pert gene in the sputum was negative, the blood and urinary phosphocalcic balance was normal, the complete immunological workup showed no abnormalities, the avian and farmer's lung precipitins were negative, and the Schirmer test was positive (Right eye 1mm; Left eye 4mm).

The chest X-ray revealed a bilateral interstitial syndrome characterized by diffuse reticulo-micronodular infiltrates predominantly in the basal regions (Figure 1). The X-ray of the hands and feet showed a degenerative appearance with joint space narrowing of the distal interphalangeal joints and diffuse bone demineralization without structural involvement. The chest CT scan indicated bilateral interstitial involvement with early fibrosis, showing a pattern suggestive of probable common interstitial lung disease (Figure 2). A bronchoscopy revealed the presence of a mass at the level of the right main bronchus and the intermediate trunk, which was whitish and bled on contact, making it uncannulable (Figure 3). A cytodiagnostic study showed reactive inflammatory cytology with no malignant cells, and a bronchial biopsy revealed bronchial mucosa with non-specific fibrous and chronic inflammatory changes. A high-resolution chest CT during forced expiration, along with brain and abdominal-pelvic CT scans, revealed interstitial lung disease with early fibrosis associated with a suspicious endobronchial tissue mass in the right bronchus, as well as airflow obstruction and signs of superinfection (Figure 4). On cervical ultrasound: Multiple left cervical lymph nodes, rounded in shape, hypoechoic and heterogeneous, with lobulated contours in some, containing anechoic areas, and some showing calcifications, visible in the left level III and V regions, with the largest measuring 2.3x1.8 cm. A lymph node biopsy revealed a poorly differentiated process with morphological and immunohistochemical features compatible with a lymph node localization of a poorly differentiated and infiltrating non-small cell pulmonary adenocarcinoma not expressing the anti-ALK antibody (Figure 5). A search for somatic mutations of the EGFR gene was negative, and the PD-L1 assay was positive at 70%. A bone scintigraphy was performed, showing no scintigraphic signs of secondary bone localization (Figure 6). A salivary gland biopsy revealed grade 4 sialadenitis according to Chisholm and Mason, with no signs of tumor proliferation (Figure 7).

The tumor was classified as T2 N0 M1b, corresponding to stage IVA. Chemotherapy was initiated with Carboplatin AUC5 and Paclitaxel 90mg/m².

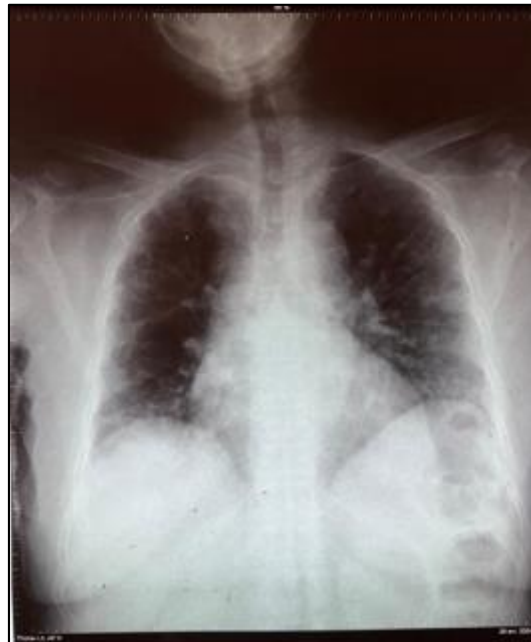

Figure 1 Bilateral interstitial syndrome on chest X-ray

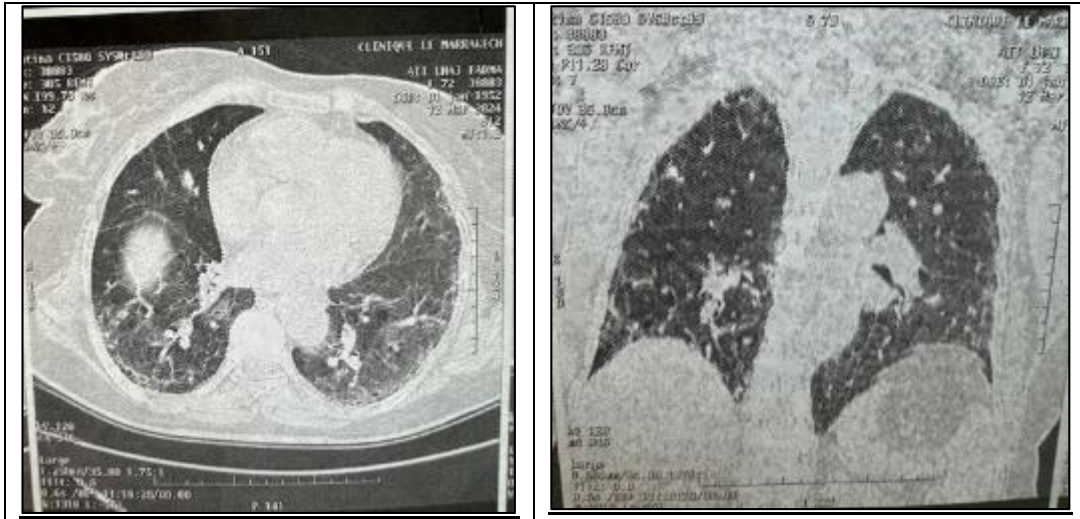


Figure 2 Chest CT with parenchymal window revealing interstitial lung disease with early fibrosis and a pattern suggestive of probable common interstitial pneumonia

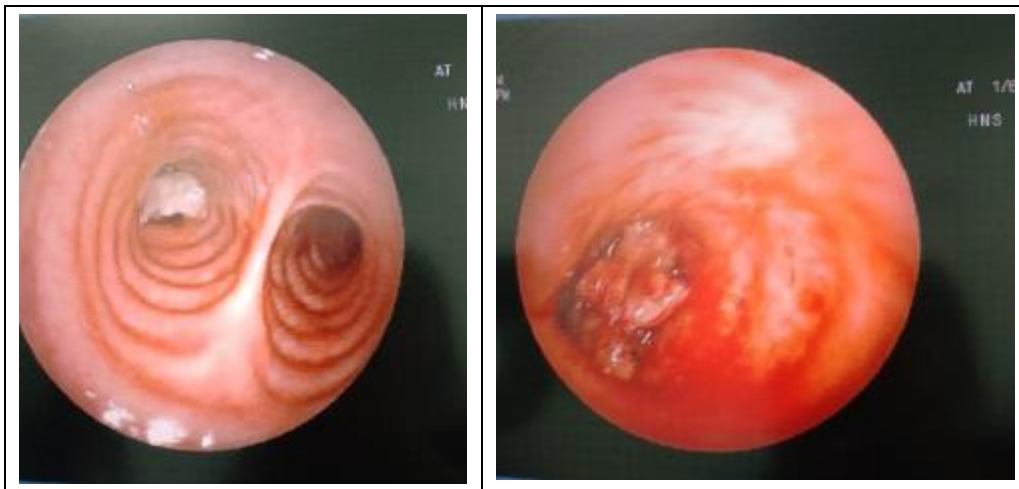

Figure 3 Pearlescent white mass at bronchoscopic examination

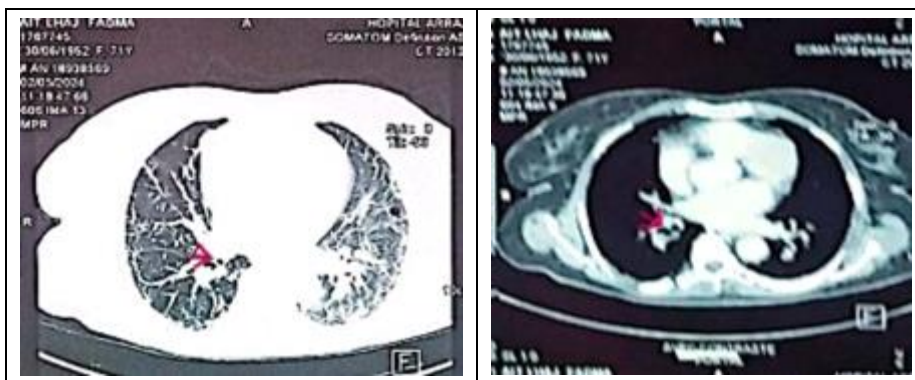


Figure 4 Interstitial lung disease with early fibrosis associated with a suspicious right endobronchial tissue mass on the TAP CT scan

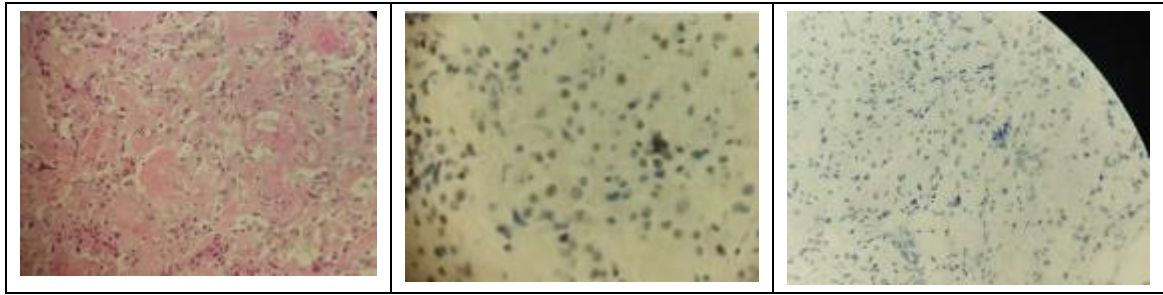


Figure 5 Poorly differentiated tumor proliferation with morphological and immunohistochemical features compatible with a lymph node localization of a poorly differentiated and infiltrating non-small cell pulmonary adenocarcinoma not expressing the anti-ALK antibody

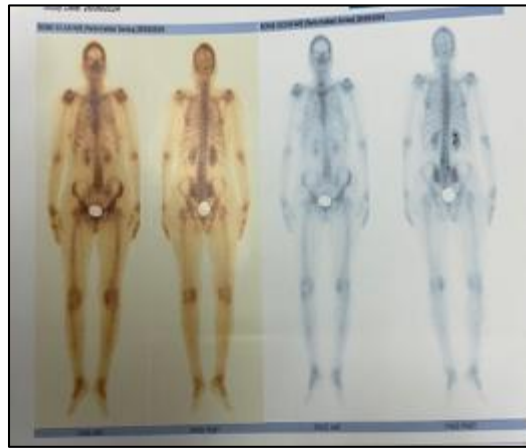


Figure 6 No bone involvement on bone scintigraphy

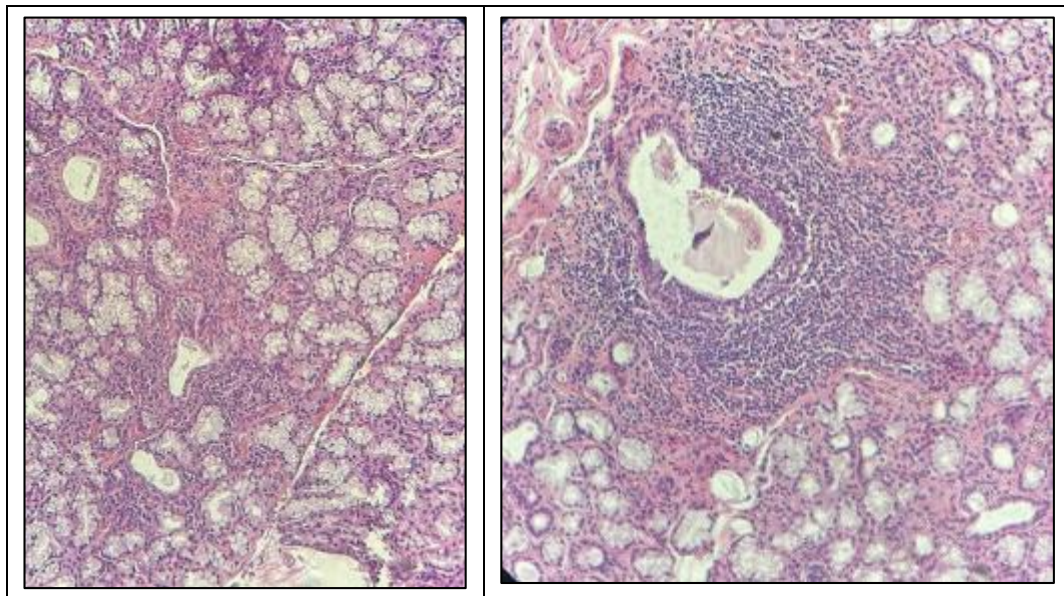


Figure 7 Histological appearance of grade 4 sialadenitis on salivary gland biopsy

3. Discussion

Sjögren's syndrome is a chronic autoimmune disease characterized by dry mouth and eyes, which can sometimes mask serious conditions such as lung cancers. The relationship between this syndrome and pulmonary adenocarcinomas is raising increasing concerns in clinical research.

Pulmonary manifestations in Sjögren's syndrome are varied, including interstitial lung involvement and pulmonary nodules, which can sometimes be interpreted as signs of malignancy. Patients may present symptoms such as persistent cough, shortness of breath, and chest pain, although these symptoms are often nonspecific [4]. The most commonly observed radiological abnormalities are ground-glass opacities, interstitial infiltrates, and pulmonary nodules [5]. Patients with Sjögren's syndrome have an increased risk of developing lymphoproliferative cancers, including lymphomas, but the risk of pulmonary adenocarcinoma is also significant. The underlying mechanisms are still under investigation, but a possible hypothesis is that the chronic inflammation associated with this syndrome may create an environment conducive to carcinogenesis [6]. Moreover, the immunological alterations inherent to the syndrome can influence tumor growth and the progression of lung cancer [7]. The early diagnosis of pulmonary adenocarcinoma in the context of Sjögren's syndrome is particularly complex due to the similarity of symptoms and radiological findings with those observed in the syndrome itself. The identification of atypical radiological features or rapid progression of pulmonary lesions should alert clinicians to the possibility of underlying malignancy [8]. The use of advanced diagnostic techniques, such as high-resolution computed tomography (HRCT) and pulmonary biopsy, is crucial for differentiating between the pulmonary manifestations of Sjögren's syndrome and the signs of adenocarcinoma [9]. Future research should aim to clarify the biological mechanisms linking Sjögren's syndrome to lung cancer, as well as develop specific screening strategies to facilitate the early detection of this malignancy in affected patients. A better understanding of biomarkers associated with this condition could also enhance more targeted and effective management of patients [10].

4. Conclusion

Gougerot-Sjögren syndrome can mask pulmonary adenocarcinomas, making precise differential diagnosis crucial. The thoracic manifestations of the syndrome require special attention to detect any potential malignancy early. Improving screening strategies and researching specific biomarkers are essential for effective and targeted patient management. Increased vigilance is necessary to avoid late diagnoses and optimize clinical care.

Compliance with ethical standards

Disclosure of conflict of interest

No conflict of interest to be disclosed.

Statement of informed consent

Informed consent was obtained from all individual participants included in the study.

References

- [1] Andeson LG, Talal N. The spectrum of benign to malignant lymphoproliferation in Sjogren's syndrome. *Clin Exp Immunol* 1971;9:199-221
- [2] Janin A, Morel P, Quinquandon I, Fabre I et al. Non-Hodgkin's Lymphoma and Sjogren's syndrome. An immunopathological study of 113 patients. *Clin Exp Rheumatol* 1992;10:565-70
- [3] Hansen LA, Prakash UBS, Colby TV. Pulmonary lymphoma in Sjogren's syndrome. *Mayo Clin Proc* 1989;64:920-315.
- [4] Fernández, J., et al. (2020). Pulmonary manifestations in Sjögren's syndrome: A comprehensive review. *Autoimmunity Reviews*, 19(10), 102-114.
- [5] Gotts, J. E., et al. (2018). Pulmonary complications in primary Sjögren's syndrome. *Chest*, 154(3), 679-689.
- [6] Vitali, C., et al. (2022). Cancer risk and prognosis in patients with Sjögren's syndrome: A systematic review and meta-analysis. *Journal of Autoimmunity*, 123, 102-113.

- [7] Michels, T. A., et al. (2019). Immunological factors in Sjögren's syndrome and cancer risk. *Immunology Today*, 40(5), 398-410.
- [8] Troncoso, G. F., et al. (2021). Diagnostic challenges in distinguishing pulmonary nodules associated with autoimmune diseases from malignancy. *American Journal of Respiratory and Critical Care Medicine*, 204(4), 517-529.
- [9] Cazzato, R. L., et al. (2023). Advanced imaging techniques for differentiating pulmonary manifestations in autoimmune diseases. *Journal of Radiology Research*, 18(2), 112-123.
- [10] Dhir, A., et al. (2024). Biomarkers in autoimmune diseases and their role in cancer detection. *Clinical Immunology Reviews*, 27(1), 45-56.